

ANOREXIC PATIENT WITH EXTREME GASTRIC DILATATION

Anoreksična pacijentica s ekstremnom dilatacijom želuca

Emilio Dijan, Jakov Mihanović, Nediljko Jović, Edgar Domini, Ivan Rakvin, Tomislav Vanjak

Abstract

Acute gastric dilatation is a rare complication of anorexia nervosa binge incident which can result in gastric necrosis, perforation and even death. We present a case of a 30-year-old anorexic female patient with abdominal pain and vomiting after an overeating episode. Emergent CT scan revealed an extremely dilated stomach with wall pneumatosis together with clinical findings of generalized guarding of distended abdomen. After median laparotomy large livid stomach without perforation was found. Decompression was achieved through gastrotomy followed by gastro-enteral and entero-enteral anastomosis. Recovery was complicated by iatrogenic pneumothorax after insertion of a central venous catheter on the right side and pleural effusion on the left side which mandated bilateral thoracic drainage. Anastomoses healed without complications in spite of low albumin level. Oral feeding route was employed with normal stool passage followed by an uneventful recovery.

Keywords

acute gastric dilatation, anorexia, binge, eating disorder

Sažetak

Akutna dilatacija želuca je rijetka komplikacija koja nastaje nakon epizode prejedanja kod osoba koje boluju od anoreksije. Posljedice mogu biti nekroza želučane stijenke, perforacija i smrt. Prikazan je slučaj 30-godišnje anoreksične bolesnice s bolovima u trbuhu i povraćanjem nakon konzumacije veće količine hrane. Zbog CT nalaza ekstremne dilatacije želuca s pneumatozom stijenke i kliničkim znacima akutnog abdomena, indiciran je operacijski zahvat. U trbušnu šupljinu pristupljeno je medijanom laparotomijom te je nađen ogromni želudac lividne stjenke, ali bez perforacije. Učinjena je gastrotomija i dekompresija, te gastro-enteralna i entero-enteralna anastomoza. Zbog

iatrogenog pneumotoraksa nakon postavljanja centralnog venskog katetera i kontralateralnog pleuralnog izljeva, učinjena je obostrana drenaža prsišta. Anastomoze su zacijelile bez komplikacija unatoč niskoj razini albumina u serumu. Započeta je peroralna prehrana te je uspostavljena uredna crijevna pasaža. Daljnji oporavak prošao je bez komplikacija.

Ključne riječi

akutna dilatacija želuca, anoreksija, prejedanje, poremećaj prehrane

Introduction

Acute gastric dilatation caused by a binge episode in an anorexic patient is a rare but documented complication [1]. It is well known that anorexia nervosa causes chronic gastric and intestine changes leading to delayed gastric emptying and slowed motility which in combination with a polyphagic incident can lead to acute gastric dilatation [2]. This is considered a surgical emergency because of imminent gastric wall necrosis and perforation. We present a case of acute gastric dilatation requiring urgent laparotomy in a patient with anorexia nervosa after an overeating episode.

Case report

A 30-year-old female with an anorexic aspect presented to the Surgical Emergency Department with a sudden onset of diffuse abdominal pain and vomiting of brownish content without fecal odour. She denied having an eating disorder, but admitted to have eaten pastry with apples and cookies the previous day. Physical examination revealed a markedly distended abdomen, diffusely tender with peritoneal signs. Her weight was 35 kg over 160 cm of height which makes body mass index (BMI) = 13. She was hypotensive, tachycardic and tachypnoic. Laboratory findings were not altered except for the albumin level of 30 g/L. After

placing a large bore nasogastric tube (18 Ch), she was immediately sent to non-enhanced abdominal computed tomography (CT) which showed extremely dilated stomach almost reaching pubic symphysis (Fig. 1), measuring 30 x 25 cm regardless of proper tube position (Fig. 2). The colon and small bowel were displaced caudally (Fig. 3). After non-satisfactory decompression through nasogastric tube and further deterioration of the pain, indication for operation was reached. During an attempt of preoperative optimization, the anesthesiologist placed a central venous catheter in the right subclavian vein at the cost of iatrogenic pneumothorax on the same side. Before the operation, a chest tube was inserted in local anesthesia (Fig. 4). Once under general anesthesia, the abdominal cavity was opened through median laparotomy and the distended stomach popped up. The stomach wall was thin and livid, near perforation, but without traces of soiling (Fig. 5). Gastrotomy was done on the greater curvature and the contents were sucked out (air, brownish liquid, undigested food – pieces of apples and cookies). Soon, the stomach reached its normal size and rapidly gained a nice pinkish colour which proved an acute rather than chronic dilatation. Gastric mucosa was vulnerable and macerated. No anatomic obstruction was found on the level of pylorus and duodenum which was patent. The operation was finished with a creation of stapler gastro-enteric and entero-enteric anastomosis using an omega loop. A long nasogastric tube was placed in an efferent loop for the purpose of early enteral feeding. Postoperative course was complicated with a left-sided pleural effusion which mandated chest drainage. The patient tolerated food well and had regular normal stools. Thoracic drains were removed after control chest X-rays showed normal expansion of the lung. The patient was transferred to the Internal Medicine Department on the 14th postoperative day for continuation of renourishment. Gastrographin study confirmed normal gastric tonus and passage of contrast into the small bowel (Fig. 6). It is interesting that the patient kept denying an eating disorder which is not uncommon in anorexia nervosa patients [3].

Discussion

Acute gastric dilatation is a rare complication in patients with anorexia nervosa. Organic causes of gastric dilatation like bulbostenosis, diabetic gastropathy, superior mesenteric artery syndrome and pancreas annulare should be ruled out. More than half of patients with anorexia have gastric dysmotility and delayed gastric emptying [4]. Predisposing factors include gastric muscular layer atrophy and changes in the autonomous nervous system. Patients with acute gastric dilatation typically present with a sudden onset of abdominal pain, distention and sometimes with inability to vomit [5]. It is important to elicit any present

or remote history of eating disorders, which patients usually deny. Maintaining a high index of suspicion of acute gastric dilatation is crucial, since delays in treatment are associated with high mortality. A possible list of complications includes gastric wall necrosis, perforation, peritonitis and even death. As the intragastric pressure rises above 30 cm H₂O, a decrease in venous outflow may result in ischemia and infarction of the gastric wall which can rupture. Mortality rates associated with gastric wall necrosis and rupture have been reported to be around 50% [6]. In our case, mucosal erosions were seen, witnessing that the process of gastric infarction was already underway. Acute gastric dilatation treatment should always start with nasogastric decompression and fluid resuscitation. In our case, no peripheral veins could be accessed and the patient continued vomiting in spite of proper placement of a large bore nasogastric tube which was probably occluded with large pieces of food. CT scan is useful in evaluation of such patients, especially concerning possible perforation or revealing mechanical cause of obstruction. However, in unstable patients operative treatment should be sought soon after initial failure of conservative treatment. This case warns that clinical findings should lead the surgeon to the diagnosis even when the patient gives misleading information about anamnestic data.

Figure 1.
Frontal CT view shows the distended stomach occupying
the entire abdominal cavity.

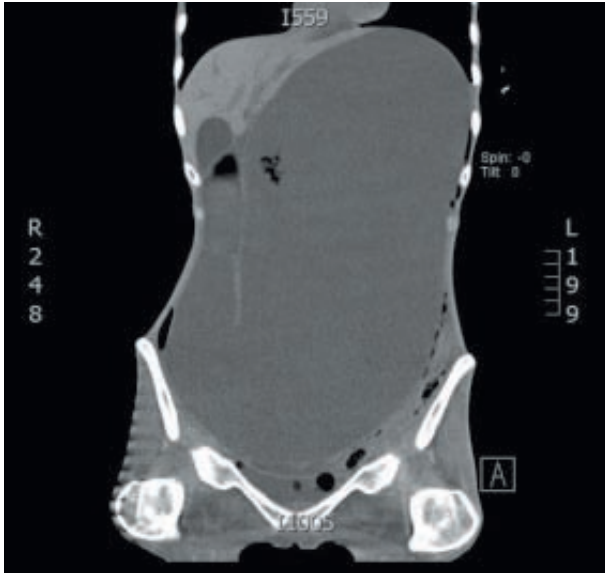


Figure 4.
Positioned chest tube before laparotomy and the distended
abdomen.

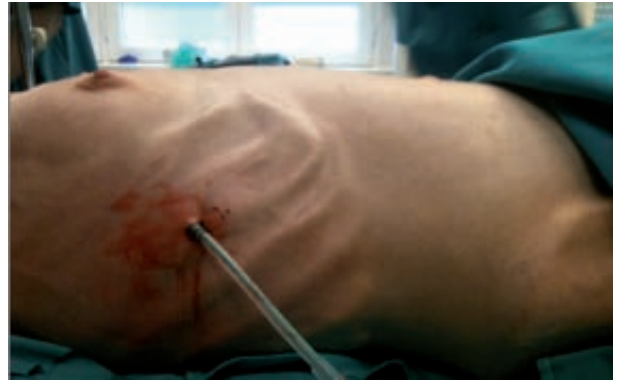

Figure 5.
The dilated stomach pops up after xypho-pubic laparotomy.

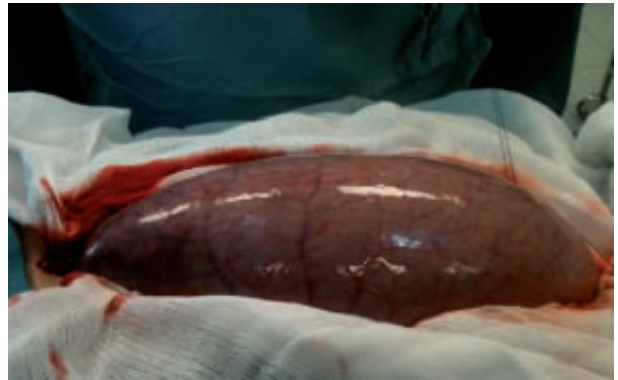


Figure 2.
Transverse CT view shows the proper nasogastric tube position.

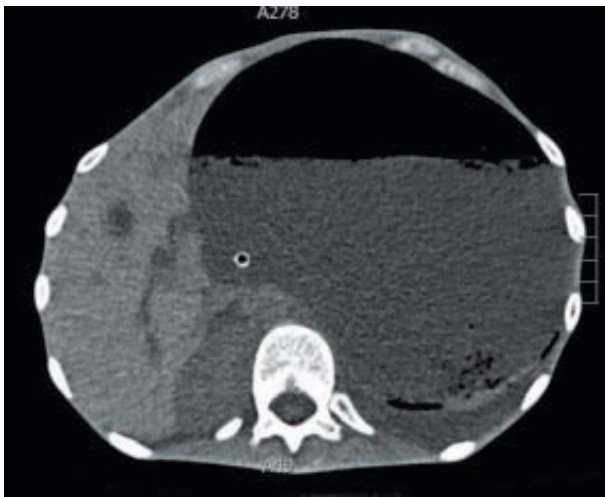
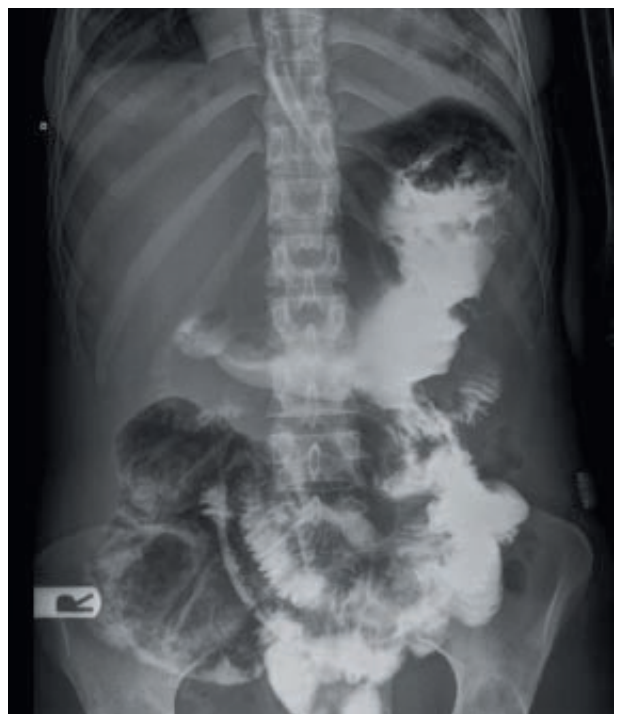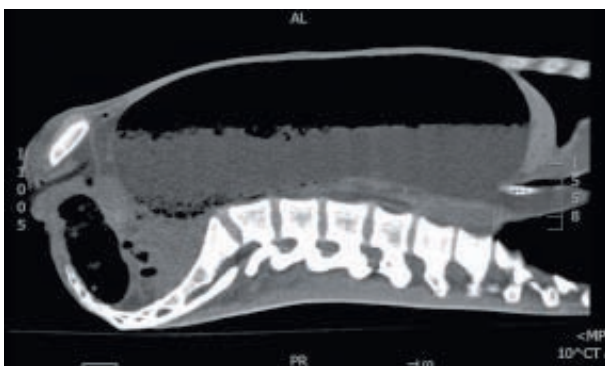


Figure 6.
Gastrographin study on the 14th postoperative day: the
stomach has returned to its normal anatomic
and physiological condition.

Figure 3.
Sagittal CT view shows the distended stomach almost reaching
pubic symphysis.



References

1. Hadley SJ, Walsh BT. Gastrointestinal disturbances in anorexia nervosa and bulimia nervosa. *Curr Drug Targets CNS Neurol Disord* 2003;2: 1–9.
2. Turan M, Sen M, Canbay E, Karadayi K, Yildiz E. Gastric necrosis and perforation caused by acute gastric dilatation: report of a case. *Surg Today* 2003;33: 302–304.
3. Vandereycken W, Van Humbeeck I. Denial and concealment of eating disorders: a retrospective survey. *Eur Eat Disord Rev* 2008;16: 109–114.
4. Nakao A, Isozaki H, Iwagaki H, Kanagawa T, Takakura N, Tanaka N. Gastric perforation caused by a bulimic attack in an anorexia nervosa patient: report of a case. *Surg Today* 2000;30: 435–437.
5. Benini L, Todesco T, Dalle Grave R, Deiorio F, Salandini L, Vantini I. Gastric emptying in patients with restricting and binge/purging subtypes of anorexia nervosa. *Am J Gastroenterol* 2004;99: 1448–1454.
6. Watanabe S, Terazawa K, Asari M, Matsubara K, Shiono H, Shimizu K. An autopsy case of sudden death due to acute gastric dilatation without rupture. *Forensic Sci Int* 2008;180: 6–10.