

## DOUBLE SCHWANNOMAS OF THE ULNAR NERVE: CASE REPORT

Filip Mustac<sup>1</sup>, Mia Poturica<sup>2</sup>, Kresimir Bulic<sup>3</sup>

### ABSTRACT

**Background:** Schwannomas are benign peripheral nerve sheath tumors, mainly solitary, well defined and with low incidence of malignant transformation. The incidence of schwannomas in hand tumors is 5%. Schwannomas are initially asymptomatic, but later due to their growth they can compress surrounding tissue and cause pain.

**Case study:** We present a case of a 68-year-old patient with a double schwannoma of the right ulnar nerve. The MRI showed a soft tissue mass which was suspected to be a schwannoma and the diagnosis was confirmed by pathohistology. Enucleation of both tumors with nerve preservation was performed and the patient is without any postoperative neurological deficit.

**Conclusion:** Intra-capsular enucleation with nerve preservation is a treatment option which may significantly lower postoperative nerve damage with an acceptable risk of local recurrence.

### Keywords:

schwannoma, magnetic resonance imaging, ulnar nerve

### INTRODUCTION

Schwannoma is a benign nerve sheath tumor which rarely turns malignant. The first schwannoma was described by Verocay in 1908. They are most commonly solitary and grow slowly. They are typically 1.5 to 3cm in diameter [1,2]. They can affect any nerve in the body, where among the hand tumors the incidence of schwannoma is 5%. After surgical removal, the incidence of recurrence is very rare. When looking among all nerves, the one most commonly affected by schwannoma is the *median nerve* [3]. In general, the schwannoma occurs more often in the nerves of the upper extremities than lower. They most commonly occur between the ages of 30 and 50. Magnetic Resonance Imaging (MRI) is the gold standard in peripheral nervous system tumor diagnosis [1]. When doing the differential diagnosis, one must consider neurofibroma, as well as the malignant peripheral nerve tumors; where the final diagnosis does require a pathohistological finding. The choice therapy is tumor

resection with as much nerve preservation as possible in order to preserve function [3].

### CASE STUDY

A year ago, sixty-eight-year-old woman noticed a lump on the hypothenar muscle of her right fist that was progressively getting larger and was painful on touch. Physical examination determined a lump size 1x1cm, of hard consistency, movable in respect to surface, and without skin changes. Pressure and percussion of the lump caused throbbing pain in the fourth and fifth finger. The patient had a palpable lump on the ulnar side of the distal forearm which was asymptomatic and looked like a ganglion cyst. As it seemed that this could be a tumorous form either originating from the ulnar nerve or pressing on it, the patient was sent for an MRI of the right wrist (Figure 1). An oval and sharply delineated form in the subcutaneous fat tissue of the palm at the level of the 5th carpometacarpal joint was visible before and after the intravenous contrast application. It measured at 0.8x0.7x0.4cm and appeared to be well vascularized. It was located on the *abductor muscle of digiti minimi* and 2mm from the *ulnar nerve*. There were no signs of infiltration of the surrounding tissue. According to the MRI characteristics, it resembled a neuroma. The exploration of the formation was done under general anesthesia and with tourniquet. The suspected tumor of the ulnar nerve in the Guyon channel was confirmed, and the formation in the distal forearm was also in the continuum with the ulnar nerve (Figure 2). An intra-capsular enucleation of both formations was performed along the line of the direct seam of one of the fascicles which was cut during the enucleation of the distal tumor.

Histologically, both nodes were made of long bundles of spindle cells whose nuclei were partially collapsing. There was a spindle capsule on the top. Pathology results determined a diagnosis of schwannoma.

### DISCUSSION:

This case was about schwannoma of the ulnar nerve. The gradual growth of the tumor leads to the compression of the nerve which may result in pain; although when it comes to schwannoma most commonly there is

<sup>1</sup>School of Medicine University of Zagreb, The Croatian Institute of Emergency Medicine, Zagreb County, Croatia

<sup>2</sup>Community Health Center Zagreb-West, Zagreb, Croatia

<sup>3</sup>School of Medicine University of Zagreb, Department of Surgery, University Hospital Centre Zagreb, Croatia

**Corresponding author:** Filip Mustac, School of Medicine University of Zagreb, The Croatian Institute of Emergency Medicine, Zagreb County, Croatia

**e-mail:** filip.mustac@gmail.com

**DOI:** 10.5281/zenodo.4010883

only a painless soft tissue growth. Very rarely, it may be manifested as a focal neuronal outbreak [3]. Due to this imprecise clinical picture there is a bigger problem with differential diagnosis, especially neurofibromas, as well as other soft tissue formations. The appearance of multiple soft tissue structures, especially in younger patients with loaded family history, should raise red flags regarding neurofibromatosis. If the patient has multiple schwannomas, but no tumor of the vestibular nerve, this could be an indication of possible schwannomatosis which is the third type of neurofibromatosis [4]. Electromyography is not of much use, except to show which nerves or plexuses are affected. Computer Tomography (CT) in the diagnosis of the soft tissue tumor structures is not the best choice because the density of the possible structures is very similar to the muscle density. CT could be useful if there is tumor calcification. MRI can detect the origination site, the position in relation to the nerve (whether it is intrinsic or extrinsic), as well as the actual structural characteristics such as irregular edges, bleeding, or necrosis [5]. Even though the MRI is very good at showing the structure, the final diagnosis can only be made through a pathohistological examination.

Pathohistological examination is used to determine the type of tumor and whether the tumor is benign or malignant. When it comes to schwannoma there are two histological regions Antoni A and Antoni B. Antoni A region consists of spiral bound spindles of Schwann cells forming palisades and producing Verocay bodies. As opposed to the hypercellular Antoni A regions, Antoni B regions are hypocellular and the Schwann cells do not have a specific arrangement within the loose connective tissue. In most tumors either Antoni A or Antoni B regions dominate. When diagnosing peripheral nerve tumors, it is very useful to perform immunohistochemical analysis which determines antibodies for S-100, CD31, CD34 and GFAP proteins [1]. Microsurgical treatment is the therapy of choice. In most cases improvement in peripheral nerve function has been achieved by enucleation, however there is a possibility of iatrogenic nerve damage. There are two enucleation techniques – extra-capsular and intra-capsular. In one study the advantages of intra-capsular enucleation of schwannoma over the extra-capsular were examined. The study had 35 patients, and 36 schwannomas. Twenty schwannomas were treated via extra-capsular enucleation, while 16 were treated via the intra-capsular. The postoperative neurological deficits were classified as light, heavy, and transient. Of the total number of patients 22 had no neurological deficit or they developed a deficit which subsided in six months. Ten patients developed a new neurological deficit which required more than six months to subside. Four patients developed a motor deficiency which continued through the publication of the study; where all patients with a motor deficiency had been treated

with extra-capsular enucleation. The study showed that intra-capsular enucleation is a safer approach to treatment than extra-capsular as there is a much lower risk of nerve injury [5]. In this case we decided on the intra-capsular enucleation as it carries a lower risk of nerve injury, especially as the patient had a tumor on two levels and where the final cumulative nerve damage could significantly compromise functioning. After the surgery, the patient did not have any obvious neurological incidents, had a two-point discrimination of 4 mm on the 4<sup>th</sup> and 5<sup>th</sup> fingertip and hand muscle strength of 5/5 innervated by an ulnar nerve.

## CONCLUSIONS

Schwannoma is a tumor of the nerve sheath which occurs with the frequency of 5% among tumors of the hand. Intra-capsular enucleation with nerve preservation is a treatment option which may significantly lower postoperative nerve damage with an acceptable risk of local recurrence.

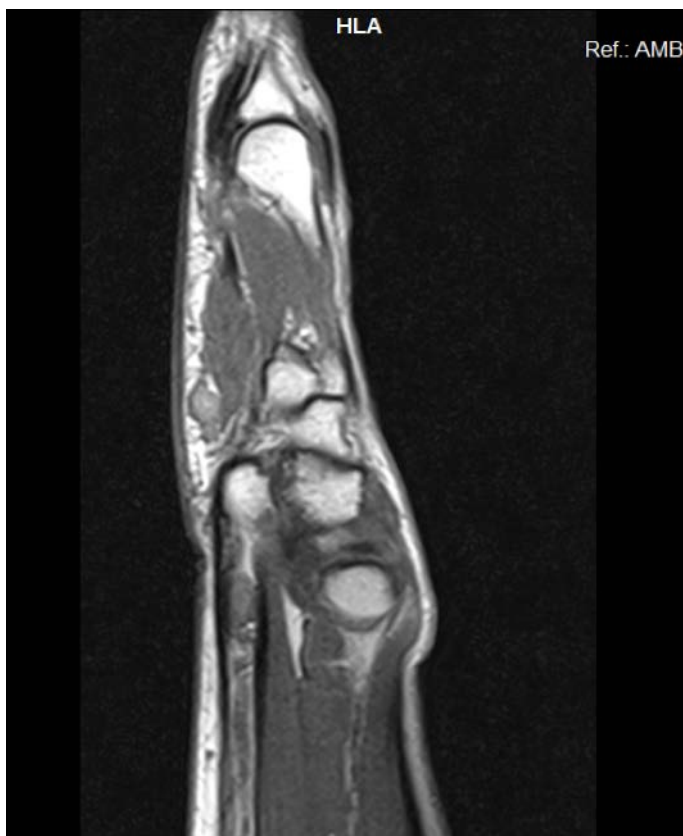
## CONFLICT OF INTEREST:

**The authors declare that there is no conflict of interest.**

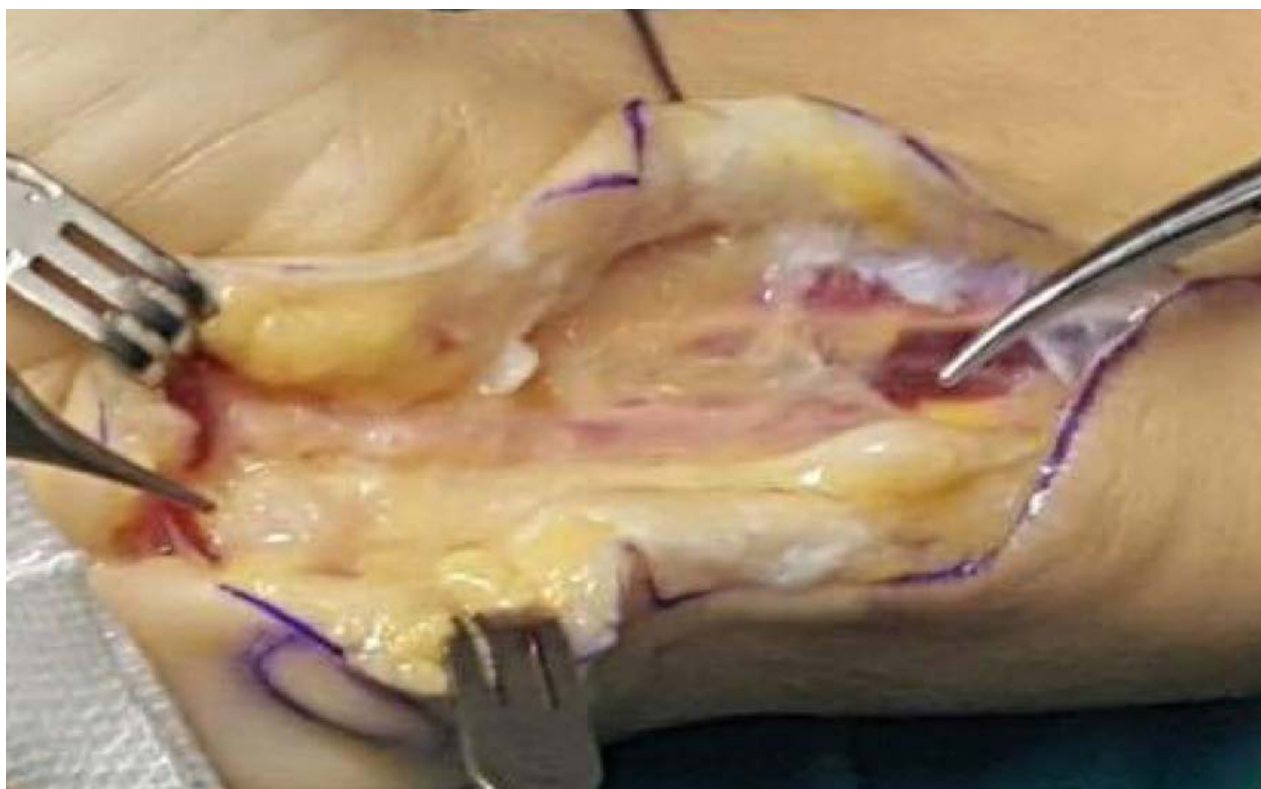**The patient gave her informed consent prior to her inclusion in case report.**

## REFERENCES:

1. Gosk J, Gutkowska O, Urban M, Wnukiewicz W, Reichert P, Ziolkowski P. Results of surgical treatment of schwannomas arising from extremities. *Biomed Res Int.* 2015;2015:547926. Viswanath S, Jain AKC. Schwannoma of the left ulnar nerve: a case report. *OA Case Reports* 2013. 24;2(16):151.
2. Baehring JM, Betensky RA, Batchelor TT. Malignant peripheral nerve sheath tumor: the clinical spectrum and outcome of treatment. *Neurology* 2003;61:696.
3. Mac Collin M, Chiocca EA, Evans DG et al. Diagnostic criteria for schwannomatosis. *Neurology.* 2005, 64:1838.
4. Pilavaki M, Chourmouzi D, Kiziridou A, Skordalaki A, Zarampoukas T, Drevelengas A. Imaging of peripheral nerve sheath tumors with pathologic correlation: pictorial review. *Eur J Radiol* 2004;52: 229.
5. Date R, Muramatsu K, Ihana K, Taguchi T. Advantages of intra-capsular micro-enucleation of schwannoma arising from extremities. *Acta Neurochir (Wien)* 2012 Jan 154(1): 173–8.



**Figure 1.** Oval and sharply constrained formation in subcutaneous fat tissue on the palm at the height of the 5th carpometacarpal joint.



**Figure 2.** Intraoperative picture of the right fist with changes in the ulnar nerve in the distal forearm and in the Guyon channel area